


Available online at [www.sciencedirect.com](http://www.sciencedirect.com)

ScienceDirect

[www.elsevier.com/locate/trap](http://www.elsevier.com/locate/trap)

## Epidural Complications and troubleshooting

Maria Teresa Bovaira-Forner, MD<sup>a,\*</sup>, Javier de Andrés Ares, MD<sup>b</sup>,  
Gisela Roca, MD<sup>c</sup>, Maria Luisa Franco Gay, MD<sup>d</sup>, Consuelo Nieto, MD<sup>e</sup>,  
Paula Bovaira, MD<sup>a</sup>

<sup>a</sup>Department of Anesthesiology, Hospital Intermutual de Levante, Ademúz, Km 11,7, 46184—San Antonio Benagéber, Valencia, Spain

<sup>b</sup>Department of Anesthesiology, Hospital Universitario La Paz, Madrid, Spain

<sup>c</sup>Department of Anesthesiology, Hospital Tries y Pujol, Badalona, Spain

<sup>d</sup>Clinica Vizcaya, Bilbao, Spain

<sup>e</sup>Department of Anesthesiology, Hospital Universitario Fundacion Alcorcon, Madrid, Spain

### ARTICLE INFO

#### Keywords:

Corticosteroid  
Epidural  
Complications

### ABSTRACT

Epidural corticosteroid infiltrations are an important option for the treatment of pain, though they are not without complications. The present review was based on a PubMed database search of articles covering the period between 1983 and 2014. The described complications can be grouped into the following categories: (1) *Infections*: The global risk of infections following epidural corticosteroid infiltration is 1%–2%, of which 0.1% prove serious. (2) *Neurologic alterations*: These complications are due to neurotoxicity (arachnoiditis or aseptic meningitis) or intra-arterial puncture and embolization of particulate corticosteroids in vertebral arteries, resulting in spinal or cerebral infarction. (3) *Bleeding*: The principal risk factor for epidural hematoma is primary or pharmacologic coagulopathy. Therefore, the decision to suspend treatment must be made according to the consensus-based clinical guides. (4) *Post-dural puncture headache*: The development of headache in these cases is less frequent than following epidural anesthesia. (5) *Pharmacologic effects of corticosteroids*: Adrenal axis suppression during 3 weeks may be observed. This has been associated with Cushing-like symptoms, mineralocorticoid effects (arterial hypertension), and blood glucose level elevation in diabetic patients. (6) *Others*: There have been reports of diminished bone mass in postmenopausal women and isolated cases of chorioretinopathy and Tachon syndrome. Epidural corticosteroid infiltration performed under radioscopic control and with contrast administration can minimize the risk of complications.

© 2015 Elsevier Inc. All rights reserved.

### Introduction

The first epidural infiltrations for the treatment of pain were performed during the 1950s. The first description of the use of

corticosteroids for the treatment of radicular pain was published by Lievre et al.<sup>1</sup> In 1961, Goebert et al.<sup>2</sup> published a series on 113 patients with lumbar radicular pain who were successfully treated using epidural injection of procaine and hydrocortisone.

\*Corresponding author.

E-mail address: [bovaira@gmail.com](mailto:bovaira@gmail.com) (M. Teresa Bovaira-Forner).

Since then, epidural corticosteroid infiltration has become an increasingly widespread practice,<sup>3</sup> and it presently constitutes an important option for the treatment of pain.

There are 3 access routes to the epidural space: interlaminar (IL), transforaminal (TF), and caudad through the sacral hiatus. The TF approach requires a lesser volume to reach the affected spinal nerve, though systematic reviews have demonstrated no significant superiority of TF epidural infiltration over the IL and caudad routes.<sup>4</sup> In principle, radioscopy appears necessary when using the TF approach, though in recent years, it has become the gold standard for performing the technique—affording greater precision in localizing the needle tip than the traditional guidance methods do (loss of resistance and pendant drop).

The clinical efficacy of the technique is currently subject to controversy. In this regard, although epidural corticosteroids appear to offer at least short-term benefit in well-selected patients, their long-term effects are less clear.<sup>5</sup> In a recent study of 400 patients with lumbar stenosis randomized to 2 treatment groups (200 patients receiving epidural glucocorticoids and lidocaine and 200 patients receiving lidocaine alone), Friedly et al<sup>6</sup> reported similar analgesic effects and functional recovery in both groups. Similar results were obtained by Manchikanti et al<sup>4</sup> in 120 patients administered TF epidural infiltrations of lidocaine with and without betamethasone.

The procedure is not without complications—the patients being exposed to significant morbidity and even isolated cases of mortality. Although the serious complications described in the literature (meningitis, epidural abscess, epidural hematoma, vascular events, or effects inherent to corticosteroid drug use) are fortunately infrequent, it is quite common for patients to develop minor adverse effects, including increased lumbar pain, paresthesias, flushing, or discomfort at the puncture site. The incidence of complications is difficult to establish, with widely varying figures in the literature, although globally it is assumed to be low. In 2 different articles, Botwin et al<sup>7,8</sup> reviewed 322 lumbar and 345 cervical TF infiltrations performed under radioscopy control—the associated incidence of complications being 9.6% and 16.8%, respectively. Another more recent retrospective study analyzed 4265 epidural corticosteroid infiltrations in 1857 patients over a 7-year period, including 161 cervical IL infiltrations, 123 lumbar IL infiltrations, 17 caudad infiltrations, and 3964 lumbar TF infiltrations. There were no major complications. Of the recorded 103 minor complications, representing an infiltration complication rate of 2.4%, the most common problem was increased lumbar pain (1.1%).<sup>9</sup>

## Methods

The present review was based on a PubMed database search of articles covering the period between 1983 and 2014 and using the following key words: epidural, corticosteroids, complications, TF, lumbar, and cervical. Some articles cited in the references of the previously selected publications were also included. The study included reviews, prospective studies with or without randomization, retrospective studies, clinical cases, and case series.

## Results

The true incidence of complications secondary to epidural corticosteroid infiltration for the treatment of pain has not been well established. However, the number of complications is probably underestimated, as many of them are not reported in the literature owing to the possible associated legal consequences. Much of the information on incidents comes from published clinical cases.

The complications described in the literature can be grouped into 6 categories, which have been described in the following sections.

### Infectious complications

According to Goodman et al,<sup>10</sup> the global risk of infections following epidural corticosteroid infiltration is 1%–2%, of which 0.1% prove serious.

Infections following epidural infiltration have been the cause of legal claims in 24 cases reported in the Closed Claim Study<sup>11</sup> and include 12 cases of meningitis, 3 cases of osteomyelitis, 7 epidural abscesses, and 2 cases of disseminated infection. Of the epidural abscesses, 6 were drained and 1 resulted in permanent motor paresis of the lower extremities.

Zimmerman et al<sup>12</sup> evaluated 36 patients with epidural abscesses over a 4-year period. The organism isolated in 4 half of the cases was *Staphylococcus aureus*. The underlying cause was primary hematogenous spread in 16 patients (44%). Among the remaining 20 patients (56%), 4 received previous epidural infiltration and 16 had undergone spinal surgery. The probability of epidural abscess formation attributable to infiltration was therefore 11.1%. These patients often present with concomitant disease conditions, fundamentally diabetes mellitus.

Hooten et al<sup>13</sup> reviewed the reports of epidural abscess secondary to corticosteroid infiltration and identified 14 cases—2 with associated meningitis. In 9 patients, the abscess manifested in the first week after puncture, whereas in 6 cases, it presented after this time. Additionally, 5 of the patients were diabetics. In 8 cases (57%), the blood, cerebrospinal fluid, or epidural pus cultures showed the presence of *Staphylococcus aureus*. Furthermore, 11 patients required laminectomy and surgical drainage, with residual motor dysfunction in 5 cases and 2 deaths.

There have also been other reports of spinal infection such as discitis<sup>14</sup> and osteomyelitis.<sup>5</sup> However, the most alarming infectious incident occurred in 2012 and corresponded with an outbreak of fungal meningitis in the United States, which was associated with a contaminated batch of methylprednisolone acetate that affected 749 patients, with 61 deaths (8%). The mean patient age was 64 years (range: 15–94 years), and 59% of the patients were female. The mean time to onset of symptoms from the last epidural infiltration was 47 days (range: 0–249 days), and *Exserohilum rostratum* was the most frequently isolated organism (20% of the cases). The clinical manifestations consisted of spinal or paraspinal infection in 31% of the patients. Further, 20% of patients presented with only meningitis and 4% with mixed meningitis and spinal

infection, and 2 patients (<1%) had spinal infection and infection of other peripheral joints.<sup>15</sup>

Quick identification of the infection and early treatment are the key factors for adequate treatment of these complications.

The way to prevent most infectious complications is to ensure thorough asepsis when preparing the skin, with special care in the case of diabetic patients. Routine antibiotic prophylaxis does not seem justified, considering the low incidence of infections, and there are not enough data to warrant antibiotic use in immune-depressed individuals. Regular antibiotic use in turn can give rise to the development of resistances. In many cases, an epidural abscess requires surgical drainage, which should be performed on an emergency basis in the presence of neurologic alterations. While the cultures are being tested, we should administer antibiotics that cover the organisms usually involved in such situations, i.e., *Staphylococcus aureus* and *S. epidermidis*<sup>5</sup> (Table 1).

### Neurologic complications

These problems can be attributed to 2 situations, which have been described here.

#### Neurotoxicity

Direct intrathecal corticosteroid injection can result in arachnoiditis or aseptic meningitis, though the underlying cause-effect relationship has not been fully clarified.

Arachnoiditis is an inflammatory process that affects the leptomeninges and underlying structures and is characterized by burning pain, muscle spasms in the back and lower extremities, sensory or motor loss, and urinary incontinence. This disorder is infrequent and is more commonly seen in patients who have undergone several spinal surgeries. The symptoms in such cases are difficult to distinguish from the

previous symptoms and which were the cause for deciding epidural infiltration. Arachnoiditis is caused by the introduction of an irritant substance within the subarachnoid space. The first reported case of iatrogenic arachnoiditis was associated with radiographic contrast administration. Nelson et al described the first 2 cases of adhesive arachnoiditis secondary to repeated intrathecal injections ( $n = 83$ ) of methylprednisolone acetate in 23 patients with advanced multiple sclerosis. The authors postulated that the problem may have been caused by the excipient (polyethylene glycol), in view of the findings of previous studies, which showed that concentrations of this substance  $\geq 78\%$  were neurotoxic.<sup>16</sup> However, the polyethylene glycol concentrations in the currently used formulations are 2.8%–3%. In a randomized, double-blinded study on 14 dogs, Lima et al analyzed the histologic changes occurring after the infiltration of methylprednisolone (1.15 mg/kg) vs 0.9% saline solution within the intrathecal space. A clinical evaluation and histologic study were performed after 21 days. There were no clinical variations in any case, though 3 of the 7 animals administered corticosteroids showed meningeal thickening with lymphocyte infiltration of the blood vessels and adherence of the pia mater, arachnoid membrane, and dura mater; spinal cord necrosis was also seen in 1 dog.<sup>17</sup>

There has also been an isolated report of arachnoiditis following caudal epidural corticosteroid infiltration.<sup>18</sup>

Another neurotoxic manifestation of corticosteroids that inadvertently penetrate the subarachnoid space is aseptic meningitis. This is a more benign condition characterized by signs of neurologic irritation, such as burning pain in the legs, headache, meningism, and, in more severe cases, seizures. The cerebrospinal fluid shows pleocytosis, increased protein concentration, and a decrease in glucose levels. In principle, aseptic meningitis can be caused by almost any substance

**Table 1 – Prevention and treatment of complications.**

Complications	Prevention	Treatment
Infections	Aseptic skin cleaning	Antibiotic coverage for <i>Staphylococcus aureus</i> Surgical drainage in case of abscess
Diabetics	Increased asepsis	
Neurologic damage	Radioscopic control Use of contrast Local anesthetic test dose Nonparticulate corticosteroids	Supportive measures High intravenous corticosteroid doses
Bleeding	Individualized antiplatelet drug suspension No suspension of NSAIDs or aspirin LMWH suspension 12 hours before Warfarin and acenocoumarol according to INR Direct anticoagulants 2-4 days	Surgical drainage in case of compressive hematoma
Dural puncture	Radioscopic control Resistance loss WITHOUT air	Conservative management Blood patch
Pharmacologic effects of corticosteroids	Spacing of infiltrations >21 days apart Lower corticosteroid doses	Extra corticosteroid doses in case of surgery
Diabetics	20 mg of triamcinolone	Metabolic control

INR, international normalized ratio.

that penetrates the intrathecal space, including blood, saline solution, or water. The condition was initially linked with the 0.9% benzyl alcohol contained in some corticosteroid formulations (methylprednisolone acetate). Deland demonstrated that 10-fold higher benzyl alcohol concentrations (9%) cause transient neurologic dysfunction but not aseptic meningitis.<sup>19</sup> Therefore, this substance does not appear to be related to aseptic meningitis.

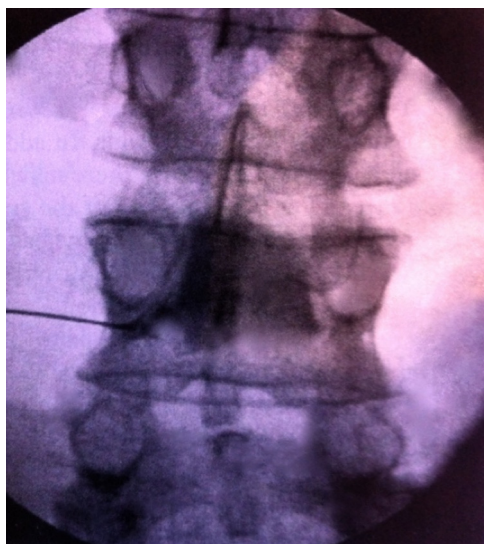A recent study has shown that the intrathecal injection  $\geq 2$  mL of Celestone Chronodose (Schering-Plough, Kenilworth, NJ) could produce histologic changes consistent with arachnoiditis, despite the formulation containing neither propylene glycol nor benzyl alcohol.<sup>20</sup>

As both arachnoiditis and aseptic meningitis are complications of the intrathecal but not epidural injection of corticosteroids, the way to prevent such problems would be to avoid inadvertent intrathecal dosing based on local anesthetic testing and the use of contrast under direct radioscopic visualization (Figure 1).

#### Neurologic damage

Neurologic damage may result from direct needle penetration of the spinal cord or the inadvertent intravascular injection of particulate corticosteroids.<sup>4</sup>

Direct needle-induced spinal cord damage is logically more frequent at cervical level and tends to be very serious, particularly when material is injected into the cord. In a recent study, Rathmell et al reviewed the incidents associated with cervical procedures for the treatment of chronic pain incidents reported between 2005 and 2008. Of the 64 identified complications, 59% corresponded to spinal cord damage. Most such problems (31%) were due to direct needle-induced injury.<sup>21</sup> These complications are related to techniques performed under deep sedation or general anesthesia and can occur with both the TF and the IL approaches. Neurologic damage is not necessarily severe or permanent, and patients may experience reversible paresis.



**Fig. 1 – Intrathecal contrast injection in transforaminal lumbar approach. (Color version of figure is available online.)**

Despite the frequent use of particulate corticosteroids in epidural infiltration, their use has not been approved by the United States Food and Drug Administration, and the complications of inadvertent intra-arterial injection can be devastating.

All the commercial particulate corticosteroid formulations contain particles that are sufficiently large to obstruct capillaries or arterioles. If injected into the vertebral artery, they can cause embolization in the posterior circulation of the central nervous system, with cerebral infarction, blindness, and even death due to intracranial hypertension. The injection of particulate corticosteroids into the spinal medullary arteries would give rise to spinal cord infarction. The location and magnitude of the neurologic damage depends on the anatomical location of the injection. Problems are more frequent following cervical TF infiltration, causing cervical spinal cord infarction with resulting permanent sensory and motor defects in all the extremities. Low spinal cord infarction occurs because of upper lumbar or thoracic infiltration. Houten and Errico published a series on 3 cases of sudden paraplegia following lumbar (2 patients) and sacral TF infiltration (1 patient). One of the patients partially recovered mobility, but not the others. The authors suggested that the underlying mechanism could be vascular damage or intra-arterial injection within an anatomical variant of the artery of Adamkiewicz, which in most cases (85%) runs from T1-L2, and in a small percentage of patients originates in the low lumbar region.<sup>22</sup> This artery runs alongside the spinal nerve through the vertebral foramen and irrigates the anterior medullary artery, which is a single vessel that vascularizes the anterior two-thirds of the spinal cord (in contrast to the 2 posterior medullary arteries, which irrigate the posterior one-third of the cord). Therefore, damage to the mentioned artery would have direct ischemic effects on the spinal cord.

In an attempt to compile the complications associated with the cervical TF injection of corticosteroids, Scalton et al<sup>23</sup> conducted a survey of interventionists specialized in pain treatment in the United States. A total of 287 of the global 1340 submitted questionnaires were completed (21.4%), with the documentation of 78 complications, which included 16 cerebral vertebrobasilar infarctions, 12 spinal cord infarctions, and 2 mixed infarctions. The cerebral infarctions were invariably characterized by involvement of the cerebellum, brainstem, and territory of the posterior cerebral artery. There were 13 deaths: 5 because of cerebral infarction, 1 due to mixed infarction, 1 associated with high spinal anesthesia, 1 associated with an epileptic attack, and 5 of unknown cause. Methylprednisolone had been used in 4 cases. Embolization of the terminal arteries has been postulated as the most likely causal mechanism. Other possible infarct mechanisms include vertebral artery damage giving rise to dissection or vasospasm induced by the needle, local compression caused by the administered volume exceeding the neural artery perfusion pressure, or the existence of previous surgery, which in itself constitutes a risk factor for spinal cord infarction.<sup>24</sup>

The way to avoid inadvertent puncture would be to use radioscopic control with the patient under mild sedation (Table 1).

In lumbosacral TF epidural infiltration under radioscopic control, the probability of vascular puncture is 8.9%–21.3%, depending on the level of injection. The usual syringe aspiration test used to assess blood return is only able to detect intravascular needle tip location in TF injections in 44.7% of the cases.<sup>25</sup> Therefore, we must use other techniques, such as local anesthetic testing, which in the case of intra-arterial needle tip placement produces dizziness, tachycardia, metallic taste, tinnitus, generalized paresthesias, and ataxia,<sup>26</sup> and contrast administration under radioscopic control *in vivo* to confirm the absence of a vascular distribution pattern.<sup>27</sup> Inadvertent intra-arterial puncture may still occur despite the adoption of such measures. Therefore, the use of digital subtraction angiography before administering the particulate corticosteroid is increasingly being recommended.<sup>28</sup>

The use of nonparticulate corticosteroids such as dexamethasone appears to offer similar efficacy without the risk associated with the particulate formulations. In a non-randomized prospective study, Lee et al compared the efficacy of triamcinolone vs dexamethasone in cervical TF infiltrations in 159 consecutive patients. No statistically significant differences in effectiveness were observed ( $P = 0.129$ ).<sup>29</sup> The same result was obtained by Shakir et al<sup>30</sup> in 441 patients with cervical radiculopathy. In turn, in a retrospective study involving 3645 lumbar TF epidural infiltrations in patients with radicular manifestations, El-Yahouchi et al compared administration of particulate corticosteroids (80 mg of triamcinolone or 12 mg of betamethasone) vs 10 mg of dexamethasone and observed no differences in clinical efficacy or functional recovery.<sup>31</sup>

Once traumatic or ischemic spinal cord damage has been inflicted, there is probably little we can do to minimize the resulting neurologic dysfunction. The administration of high-dose intravenous corticosteroids immediately after the lesion is produced has been shown to induce a significant reduction in neurologic damage.<sup>32</sup>

#### Others

The literature also describes cases of epileptic activity following epidural infiltration related to the intra-arterial injection

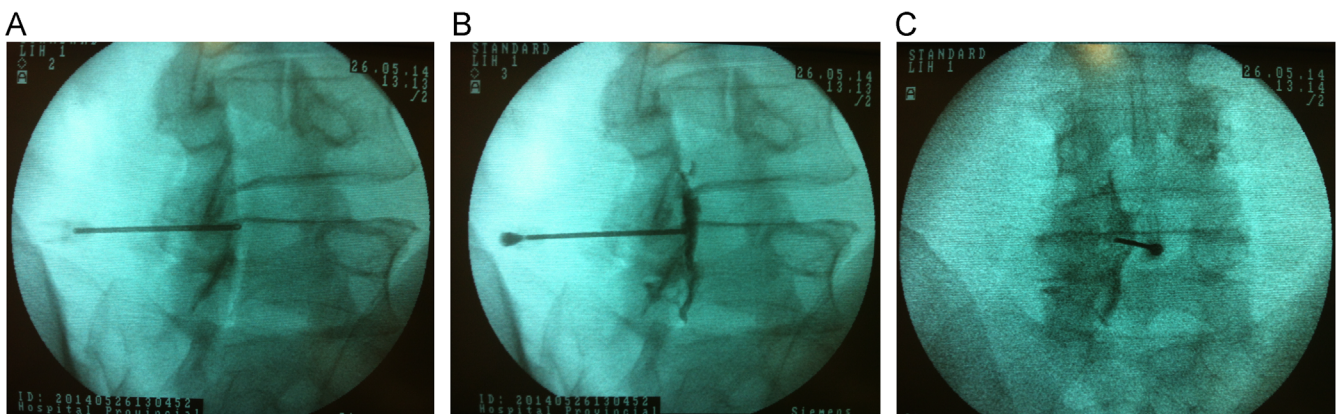
of dilutions with local anesthetics. Woo and Park<sup>33</sup> postulated that a decrease in the concentration of the local anesthetic may result in a decrease in the incidence of such events.

On the basis of these data, the Multisociety Pain Workgroup (American Society of Anesthesiologists, American Society of Neuroradiologists, International Spine Intervention Society, and others) developed a series of safety recommendations for epidural corticosteroid infiltration, with the aim of influencing the safety committee of the U S Food and Drug Administration.<sup>34</sup> The recommendations are summarized as follows:

- Radioscopic control should be used in all epidural infiltrations, regardless of the approach or localization (Figure 2).
- Cervical interlaminar infiltrations preferably should be performed at the L7-T1 level, with the avoidance of infiltrations above C6-C7 level.
- Transforaminal approaches should be made under adequate radioscopic control, using anteroposterior, lateral, or oblique contralateral projections. Contrast should be administered under direct radioscopic or digital subtraction angiographic control before administering any drug that might pose a risk for the patient.
- Nonparticulate corticosteroids should be used for cervical transforaminal infiltrations.
- In principle, nonparticulate corticosteroids should be used in lumbar transforaminal infiltrations, though in some cases, particulate formulations can be used.
- Contrast injection is not to be used in concrete cases such as patients with known allergy to the contrast medium. In these cases, the use of particulate corticosteroids is contraindicated, and dexamethasone should be used.
- Moderate or deep patient sedation is not recommended when performing epidural infiltrations. If mild sedation is used, the patient must maintain the capacity to respond and report possible pain or other undesirable effects.

#### Bleeding complications

Epidural hematomas associated with epidural infiltrations can have very serious consequences such as paraplegia or tetraplegia. The most directly related risk factor is



**Fig. 2 – Contralateral oblique view in lumbar interlaminar epidural injection. (A) Needle located in spinolaminar line. (B) Contrast distribution in spinolaminar line. (C) Contrast distribution in anteroposterior view. (Color version of figure is available online.)**

primary anticoagulant or antiplatelet drug-related coagulopathy.

Epidural hematomas may develop despite utilizing careful technique and radioscopic control. The bleeding that results in epidural hematoma formation often comes from the internal vertebral venous plexus, also known as Batson plexus. Venous leaking can accumulate blood during the day, and the patient experiences symptoms when the hematoma reaches a critical size and compresses the spinal cord or nerve root, producing ischemia.

The Closed Claim Study documents 2 cases of spinal cord injury secondary to epidural hematomas in patients treated with anticoagulants.<sup>11</sup> The series of incidents following cervical TF epidural infiltration described by Rathmell et al<sup>21</sup> includes 3 cases of epidural hematoma—one of them manifesting a month after the procedure. In these cases, there were no antecedents of coagulation disorders or anticoagulant therapy. A case of perineural hematoma following lumbar TF infiltration has also been described in a female patient without predisposing factors.<sup>35</sup>

According to a study documenting vascular incidents in pain management procedures, thrombotic events are 3 times more frequent than bleeding phenomena are (162 vs 55 cases, respectively). Among the thrombotic events, 153 occurred after suspending anticoagulant medication and 9 after suspending antiplatelet therapy. In turn, 29 of the bleeding events occurred after suspending antiplatelet medication and warfarin, whereas 26 occurred despite the continuation of anticoagulation.<sup>36</sup>

The recommendations on interrupting antiplatelet drugs such as clopidogrel, ticlopidine, or prasugrel vary, though the ultimate aim is to avoid bleeding during interventional techniques and to prevent cerebrovascular or cardiovascular thromboembolic problems. The decision to maintain or suspend such treatment must be individualized according to the background condition of the patient, the risk factors, the planned procedure, and the opinion of the cardiologist. However, there does appear to be agreement on continuing treatment with nonsteroidal anti-inflammatory drugs, including aspirin or phosphodiesterase inhibitors such as dipyridamole, cilostazol, and AGGRENOX, during invasive procedures. Low-molecular-weight heparin should be suspended 12 hours before the technique is carried out. Warfarin and acenocoumarol are to be suspended until the international normalized ratio reaches 1.4 or less in high-risk procedures and 2 in low-risk interventions, administering low-molecular-weight heparin bridging therapy if needed.<sup>37</sup> Special mention must be made of direct anticoagulants such as dabigatran, which require prior suspension with a safety interval that varies according to the half-life of the drug employed (2–4 days) (Table 1).

In the case of progressive neurologic impairment suggesting the presence of a hematoma, neuroimaging evaluation is indicated, with hematoma drainage in the first 8 hours after the onset of symptoms.<sup>38</sup>

### Dural puncture

The incidence of post-dural puncture headache is more than 50%.<sup>5</sup> However, the overall incidence of dural puncture during

epidural infiltration is low and logically depends on the skill and experience of the physician performing the technique. Such problems are more common when the IL approach is used. In a recent study, Manchikanti et al<sup>39</sup> documented 6 cases of dural puncture in 457 IL epidural infiltrations performed under radioscopic control (1.3%). No post-dural puncture headaches were recorded. The incidence of headache is lower following epidural corticosteroid infiltration than after epidural anesthesia. This is explained by the frequent use of radioscopy during performance of the technique, the patients being older, and the use of smaller-caliber needles.

The penetration of air into the subarachnoid or subdural space can give rise to pneumocephalus and immediate headache that can last for several days. The fundamental cause is inadvertent dural puncture during the loss of resistance with air technique, though it has also been described at the cervical level with the pendant drop method.

In principle, the management of post-dural puncture headache is conservative, with bed rest, adequate hydration, the administration of caffeine, and common analgesic use. If the condition fails to improve, a blood patch at the same point where dural puncture occurred usually affords a rapid and effective solution<sup>5</sup> (Table 1).

### Pharmacologic effects of corticosteroids

The administration of exogenous glucocorticoids can produce Cushing-like symptoms, with a characteristic adipose tissue distribution, a full moon face, hump, hirsutism, and eczema or skin hematomas. They can also exert mineralocorticoid actions such as fluid retention, weight increase, and a rise in blood pressure. The commercial corticosteroid formulations commonly used in epidural infiltrations are slowly released over a period of days or weeks. Consequently, these Cushing-like manifestations can develop weeks after infiltration.<sup>5</sup>

In a classical study, Jacobs et al<sup>40</sup> evaluated adrenal cortical function in 12 patients after an epidural injection of 80 mg of methylprednisolone acetate as treatment for chronic sciatic nerve pain. They observed an important decrease in plasma cortisol concentration and a decreased response to external adrenocorticotrophic hormone in 3 weeks. In a more recent study, Younes et al<sup>41</sup> subjected 18 patients to 3 epidural injections of cortivazol (equivalent to 85 mg of prednisone) at 3-day intervals and recorded suppression of adrenal cortical function that lasted 21 days. The blood pressure values were temporarily elevated.

These data suggest that epidural corticosteroid infiltration should only be repeated in patients capable of obtaining significant symptom relief and that the infiltrations should be spaced sufficiently apart to allow adrenocortical functional recovery. If the patients are to be operated on a few weeks after the epidural injection of depot corticosteroid formulations, they should receive extra corticosteroid doses as coverage against surgical stress.

On the contrary, glucocorticoid administration reduces the blood glucose level-lowering effect of insulin and interferes with blood glucose control in diabetic patients. A number of studies have evaluated the effect of depot corticosteroid formulations administered via the epidural route on the

blood glucose levels of diabetic patients—a significant increase being observed during 2 or 7 days, depending on the corticosteroid used. Kim et al,<sup>42</sup> in a prospective study of 109 diabetic individuals programmed for epidural corticosteroid infiltration, randomized the patients to 2 groups that were administered either 20 or 40 mg of triamcinolone. A significant increase in blood glucose was observed in the first 4 days after injection, and this increase was greater in the group that received 40 mg. There were no variations in analgesic efficacy in the 2 groups. It is therefore advisable to administer low doses (20 mg) of triamcinolone in epidural infiltrations in diabetic patients (Table 1).

There have also been reports of menstrual problems secondary to transient reductions in estradiol concentration, with no alterations in the follicle-stimulating hormone or luteinizing hormone levels.<sup>43</sup> Suh-Burgmann et al recorded a 2.8% increase in metrorrhagia following epidural corticosteroid infiltration in both premenopausal and postmenopausal women. This was attributed to different reasons: lysis of the endothelial stroma, inherent to anovulatory bleeding, and local alterations in prostaglandin synthesis that inhibit platelet aggregation.<sup>44</sup>

#### Other adverse effects

The literature describes a series of minor complications associated with epidural puncture, such as vagal reactions, increased pain, paresthesias, pain at the puncture site, and allergic reactions to the local anesthetics or contrast media employed.

Kang et al<sup>45</sup> reported a decrease in bone density among postmenopausal women administered epidural corticosteroids as treatment for lumbar pain, with cumulative doses of more than 120 mg of triamcinolone and established comparisons with a control group treated with anti-inflammatory drugs and muscle relaxants. However, the total glucocorticosteroid dose has not been correlated with the incidence of pathologic fractures.<sup>46</sup>

Iida et al<sup>47</sup> described 3 cases of central serous chorioretinopathy following epidural corticosteroid infiltration as therapy for lumbar pain.

Epidural corticosteroids have been associated with Tachon syndrome, characterized by intense discomfort associated with incoercible chest or lumbar pain within minutes after injection, and which occurs in 1 of 8000 infiltrations. The diagnosis is difficult to establish, and the condition must be distinguished from aortic dissection, particularly when associated with abdominal pain, transient hypertension, hypotension, or dry cough.<sup>43</sup>

There have also been isolated reports of temporary dysphonia secondary to vocal cord edema or persistent hiccup and psychiatric alterations such as mania or paranoia.<sup>43</sup>

#### Conclusion

Complications of epidural corticosteroid infiltration are infrequent but can be devastating. With the exception of the fungal meningitis outbreak registered in the United States in 2012, the most serious complications are related to the embolization of particulate corticosteroids in the vertebral

arteries (particularly at cervical level) and spinal canal occupation by hematomas or purulent accumulations that can compress the spinal cord.

The Multisociety Pain Workgroup has established a series of safety recommendations for epidural corticosteroid infiltration, including the routine use of radioscopic control, in vivo contrast injection, and the use of nonparticulate corticosteroids—particularly when cervical techniques are planned.

Mention also must be made of the particular characteristics referred to diabetic patients who require careful asepsis of the skin before injection and the administration of lower corticosteroid doses, which have demonstrated similar clinical efficacy with lesser blood glucose level elevations.

#### REFERENCES

- Lievre J, Bloch-Mitchel H, Pean G, et al. L'hydrocortisone en injection locale. *Rev Rhumatisme Mal Ostéo-articulaires*. 1953; 20:310–311.
- Goebert H, Jallo S, Gardner W, Wasmuth CE. Painful radiculopathy treated with epidural injections of procaine and hydrocortisone acetate: results in 113 patients. *Curr Res Anesth Analg*. 1961;40:130–134.
- Manchikanti L, Buenaventura RM, Manchikanti KN, et al. Effectiveness of therapeutic lumbar transforaminal epidural steroid injections in managing lumbar spinal pain. *Pain Physician*. 2012;15:E199–E245.
- Manchikanti L, Cash KA, Pampati V, Falco FJ. Transforaminal epidural injections in chronic lumbar disc herniation: a randomized, double-blind, active-control trial. *Pain Physician*. 2014;17:E489–E501.
- Cohen SP, Bicket MC, Jamison D, Wilkinson I, Rathmell JP. Epidural steroids. A comprehensive, evidence-based review. *Reg Anesth Pain Med*. 2013;38(3):175–200.
- Friedly JL, Comstock BA, Turner JA, et al. A randomized trial of epidural glucocorticoid injections for spinal stenosis. *N Engl J Med*. 2014;371:11–21.
- Botwin KP, Gruber RD, Bouchlas CG, et al. Complications of fluoroscopically guided transforaminal lumbar epidural injections. *Arch Phys Med Rehabil*. 2000;81(8):1045–1050.
- Botwin KP, Castellanos R, Rao S, et al. Complications of fluoroscopically guided interlaminar cervical epidural injections. *Arch Phys Med Rehabil*. 2003;84(5):627–633.
- Mcgraff JM, Schaefer MP, Malkamaki DM. Incidence and characteristics of complications from epidural steroid injections. *Pain Med*. 2011;12:726–731.
- Goodman BS, Posecion LW, Mallempati S, Bayazitoglu M. Complications and pitfalls of lumbar interlaminar and transforaminal epidural injections. *Curr Rev Musculoskelet Med*. 2008;1(3-4):212–222.
- Fitzgibbon D, Posner K, Domino KB, Caplan RA, Lee LA, Cheney FW. Chronic pain management American Society of Anesthesiologists Closed Claim Project. *Anesthesiology*. 2004; 100:98–105.
- Zimmerman SM, Conen A, Müller A, et al. Spinal epidural abscess: etiology, predisponent factors and clinical outcomes in a 4-year prospective study. *Eur Spine J*. 2011;20:2228–2234.
- Hooten WM, Kinney MO, Huntoon MA. Epidural abscess and meningitis after epidural corticosteroid injection. *Mayo Clin Proc*. 2004;79:682–686.
- Hooten WM, Mizerak A, Carns PE, Huntoon MA. Discitis after lumbar epidural corticosteroid injection: a case report and analysis of the case report literature. *Pain Med*. 2006;7(1): 46–51.

15. Smith RM, Schaefer MK, Kainer MA, et al. Fungal infections associated with contaminated methylprednisolone injections. *N Engl J Med*. 2013;369:1598–1609.
16. Nelson D, Vates T, Thomas R. Complications from intrathecal steroid therapy in patients with multiple sclerosis. *Acta Neurol Scand*. 1973;49:176–188.
17. Lima RM, Navarro LH, Carness JM, et al. Clinical and histological effects of the intrathecal administration of methylprednisolone in dogs. *Pain Physician*. 2010;13:493–501.
18. Nanjayan SK, Swamy GN, Yallappa S, Bommireddy R. Arachnoiditis following caudal epidural injections for the lumbosacral radicular pain. *Asian Spine J*. 2013;7(4):355–358.
19. Deland F. Intrathecal toxicity studies with benzyl alcohol. *Toxicol Appl Pharmacol*. 1973;25:153–156.
20. Latham JM, Fraser RD, Moore RJ, Blumbergs PC, Bogduk N. The pathologic effects of intrathecal betamethasone. *Spine*. 1997;22:1558–1562.
21. Rathmell JP, Michna E, Fitzgibbon DR, Stephens LS, Posner KL, Domino KB. Injury and liability associated with cervical procedures for chronic pain. *Anesthesiology*. 2011;114:918–926.
22. Houten JK, Errico TJ. Paraplegia after lumbosacral nerve root block: report of three cases. *Spine J*. 2002;2:70–75.
23. Scanlon GC, Moeller-Betram T, Romanowsky SM, Wallace MS. Cervical transforaminal epidural steroid injections: more dangerous than we think? *Spine*. 2007;32(11):1249–1256.
24. Gharibo C, Koo C, Chung J, Moroz A. Epidural steroid injections: an update on mechanism of injury and safety. *Tech Reg Anesth Pain Manag*. 2009;13:266–271.
25. Furman MB, O'Briaen EM, Zgleszewski TM. Incidence of intravascular penetration in transforaminal lumbosacral epidural steroid injections. *Spine*. 2000;25:2628.
26. Smuck M, Maxwell MD, Kennedy D, Rittenberg JD, Lansberg MG, Plataras CT. Utility of the anesthetic test dose to avoid catastrophic injury during cervical transforaminal epidural injections. *Spine J*. 2010;10(10):857–864.
27. Smuck M, Fuller BI, Yoder B, Huerta J. Incidence of simultaneous epidural and vascular injection during lumbosacral transforaminal epidural injections. *Spine J*. 2007;7(1):79–82.
28. El Abd OH, Amadera 1 JE, Pimentel DC, Pimentel TS. Intravascular flow detection during transforaminal epidural injections: a prospective assessment. *Pain Physician*. 2014;17:21–27.
29. Lee JW, Park KW, Chung SK, et al. Cervical transforaminal epidural steroid injection for the management of cervical radiculopathy: a comparative study for particulate versus non-particulate steroids. *Skeletal Radiol*. 2009;38(11):1077–1082.
30. Shakir A, Ma V, Mehta B. Comparison of pain score reduction using triamcinolone vs. Dexamethasone in cervical transforaminal epidural steroid injections. *Am J Phys Med Rehabil*. 2013;92(9):768–775.
31. El-Yahouchi C, Geske JR, Carter RE, et al. The noninferiority of the nonparticulate steroid dexamethasone vs the particulate steroids betamethasone and triamcinolone in lumbar transforaminal epidural steroid injections. *Pain Med*. 2013;14(11):1650–1657.
32. Hall E, Springer J. Neuroprotection and acute spinal cord injury: a reappraisal. *NeuroRx*. 2004;1:80–100.
33. Woo JH, Park HS. Cervical transforaminal epidural block using low-dose local anesthetic: a prospective, randomized, double-blind study. *Pain Med*. 2014;7 [Epub ahead of print].
34. Manchikanti L, Falco FJE, Benyamin RM, Gharibo CG, Candido KD, Hirsch JA. Epidural steroid injections safety recommendations by the Multisociety Pain Workgroup (MPW): more regulations without evidence or clarification. *Pain Physician*. 2014;17:E575–E588.
35. Desai MJ, Dua S. Perineural hematoma following lumbar transforaminal steroid injection causing acute-on-chronic lumbar radiculopathy: a case report. *Pain Pract*. 2014;14(3):271–277.
36. Manchikanti L, Benyamin R, Swicegood J, et al. Assessment of practice patterns of perioperative management of antiplatelet and anticoagulant therapy in interventional pain management. *Pain Physician*. 2012;15:E955–E968.
37. Manchikanti L, Falco FJE, Benyamin RM, et al. Assessment of bleeding risk of interventional techniques: a best evidence synthesis of practice patterns and perioperative management of anticoagulant and antithrombotic therapy. *Pain Physician*. 2013;16:SE261–SE318.
38. Bloodworth DM, Pérez-Toro MR, Nouri KH. Neurological deficits after epidural steroid injection: time course, differential diagnosis, management, and prognosis suggested by review of case reports. *Pain Med*. 2008;9:S41–S57.
39. Manchikanti L, Singh V, Cash KA, Pampati V, Falco FJ. The role of fluoroscopic interlaminar epidural injections in managing chronic pain of lumbar disc herniation or radiculitis: a randomized, double-blind trial. *Pain Pract*. 2013;13(7):547–558.
40. Jacobs S, Pullan P, Potter J, Shenfield GM. Adrenal suppression following extradural steroids. *Anaesthesia*. 1983;38:953–956.
41. Younes M, Neffati F, Touzi M, et al. Systemic effects of epidural and intra-articular glucocorticoid injections in diabetic and non-diabetic patients. *Joint Bone Spine*. 2007;74(5):472–476.
42. Kim WH, Sim WS, Shin BS, et al. Effects of two different doses of epidural steroid on blood glucose levels and pain control in patients with diabetes mellitus. *Pain Physician*. 2013;16(6):557–568.
43. Berthelot JM, Le Golf B, Maugars Y. Side effects of corticosteroid injections: what's new? *Joint Bone Spine*. 2013;80(4):363–367.
44. Suh-Burgmann E, Hung YY, Mura J. Abnormal vaginal bleeding after epidural steroid injection: a paired observation cohort study. *Am J Obstet Gynecol*. 2013;209(206):e1–e6.
45. Kang SS, Hwang BM, Son H, Cheong IY, Lee SJ, Chung TY. Changes in bone mineral density in postmenopausal women treated with epidural steroid injections for lower back pain. *Pain Physician*. 2012;15(3):229–236.
46. Yi Y, Hwang B, Son H, Cheong I. Low bone mineral density but not epidural steroid injection, is associated with fracture in postmenopausal women with low back pain. *Pain Physician*. 2012;15:441–449.
47. Iida T, Spaide RF, Negrao SG, Carvalho CA, Yannuzzi LA. Central serous chorioretinopathy after epidural corticosteroid injection. *Am J Ophthalmol*. 2001;132:423–425.